

Established 1994  
Privately owned

**All Appointments**  
**5478 2037**  
Fax 5444 7816

**Dr Andrew Southee**

MBBS(Hons), MRCP(UK), FRACP, AANMS

**Dr Stewart Davidson**

MBBS(Hons), FRACP, AANMS

Consultant Physicians

#### 4 SITE LOCATIONS

**Buderim**

QDI X-ray Rooms  
Shop 5, 12 King Street  
BUDERIM 4556

**Nambour General Hospital**

Ground Floor  
Block 2A  
Hospital Road  
NAMBOUR 4560

**Caloundra**

QDI X-ray Rooms  
18 Mayes Avenue  
CALOUNDRA 4551

**Noosaville**

QDI X-ray Rooms  
Noosa Private Hospital  
111 Goodchap Street  
NOOSAVILLE 4566

All correspondence:  
PO Box 5822  
Maroochydore BC  
Qld 4558

manager@ncnm.com.au

#### PATIENT DETAILS

Name

Address

DOB

Telephone

#### EXAMINATION

#### CLINICAL HISTORY

#### REFERRING DOCTOR

Name

Address

Signature

Date

Appointment Details:  
(complete when known)

Date:

Time:

Site:  Buderim  
 Nambour  
 Caloundra  
 Noosaville

PLEASE BRING ALL RELEVANT X-RAYS  
AND PREVIOUS SCANS

**ALL MEDICARE REBATABLE PROCEDURES ARE BULK BILLED**

Report to be  Returned with Patient  Courier  Faxed  Email



## DIAGNOSTIC NUCLEAR MEDICINE

Clinics utilise hybrid SPECT/low dose CT systems. This technique is used for anatomical localisation and attenuation correction (eg for cardiac perfusion studies). It has proven useful in benign and malignant conditions affecting the skeleton (particularly in the spine and pelvis), and soft tissue tumours and infection.

<b>Bone Scan</b>	Bone metastases, osteomyelitis, stress fractures, bone tumours, arthritis, loose prosthesis, osteonecrosis, RSD and tumour staging.
<b>Thyroid Scan</b>	Thyroid nodules, goitre, all causes of hyperthyroidism, thyroiditis.
<b>Parathyroid Scan</b>	Localisation of parathyroid adenoma using myocardial perfusion isotopes.
<b>Myocardial Perfusion</b> (thallium/sestamibi)	Assessment of myocardial ischaemia and viability. For patients unable to exercise dipyridamole or dobutamine (for asthmatics) are used.
<b>Lung Scan</b>	Ventilation and perfusion-pulmonary emboli. More sensitive and far less radiation than helical CTPA. Regional quantification. Right to left shunts.
<b>Renal Scan (DTPA)</b> (+/-captopril or frusemide)	Differential renal function, renovascular hypertension, ureteric obstruction MAG3 is substituted in children. GFR quantification if requested.
<b>Renal Scan (DMSA)</b>	Renal scarring and acute pyelonephritis (more sensitive than ultrasound). Differential function (particularly if one kidney is small or ectopic).
<b>Gallium Scan</b>	Lymphoma staging and response to treatment. PUO. Sarcoidosis. Chronic infections, eg osteomyelitis and infected joint prosthesis.
<b>White Cell Scan (Tc)</b>	Localisation of acute or subacute infection. Assessment of activity of inflammatory bowel disease.
<b>Colloid Liver Scan</b>	Diffuse or chronic liver disease. Assessment of liver nodules (FNH)
<b>Labelled Red Cell Scan</b>	Haemangioma of the liver. Gastrointestinal haemorrhage.
<b>Biliary Scan (HIDA)</b>	Acute cholecystitis. Biliary obstruction or dysfunction. CCK used for chronic cholecystitis or sphincter of Oddi dysfunction.
<b>Lymphoscintigraphy</b>	Sentinel node localisation in breast cancer and melanoma. Assessment of lymphoedema and lymphatic drainage.
<b>Cerebral perfusion</b> (Ceretek or ECD)	Dementias and cognitive impairment and cerebrovascular disease.
<b>Gastric Emptying</b>	Quantitative assessment of solid gastric emptying using a labelled egg sandwich. Half clearance time and % retained at 3 hours are calculated.
<b>Colonic Transit</b>	Small and large bowel clearance using sequential images over 5 days.
<b>Lacrimal Scan</b>	Functional nasolacrimal duct obstruction.

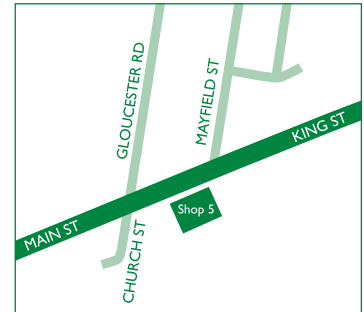## NUCLEAR MEDICINE THERAPY

<b>Radioactive iodine (I-131)</b>	Treatment of hyperthyroidism.
<b>Samarium-153, Strontium-90</b>	Palliative treatment of painful osteoblastic bone metastases. (Can only be prescribed by a specialist)
<b>Phosphorus-32</b>	Polycythaemia rubra vera and essential thrombocythaemia. (Can only be prescribed by a specialist)

## PATIENT PREPARATION

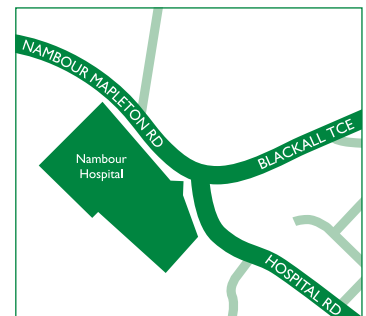
- Bone Scan - well hydrated. Images performed 2-3 hours after injection and take up to 1 hour.
- Myocardial perfusion scan (thallium, sestamibi)- fast for 3 hours after a light breakfast, then have clear fluids sparingly. No tea or coffee for 24 hours. Omit betablockers for at least 24 hours. More detailed written information is provided.
- Biliary Scans (HIDA, HIDA/CCK) fast for 4 hours.
- Gastric emptying - fast 8 hours.
- Renal Scans - well hydrated. If renal artery stenosis is being assessed ACE inhibitors need to be reviewed.
- Most other procedures have no special preparation.

### BUDERIM



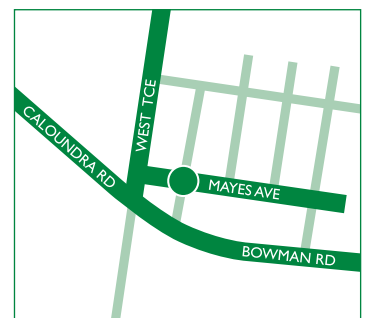QDI X-ray Rooms  
Shop 5, 12 King Street

### NAMBOUR



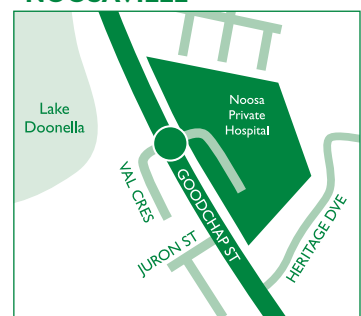
Nambour General Hospital  
Ground Floor, Block 2A  
Hospital Road

### CALOUNDRA



QDI X-Ray rooms  
18 Mayes Avenue

### NOOSAVILLE



QDI X-ray Rooms  
Noosa Private Hospital  
111 Goodchap Street